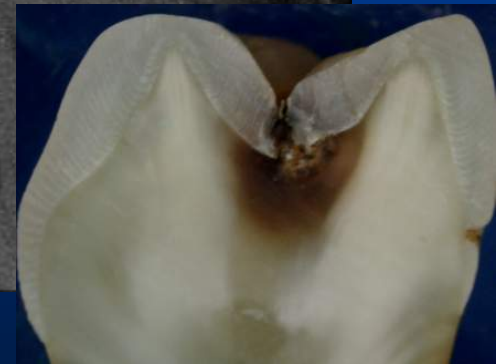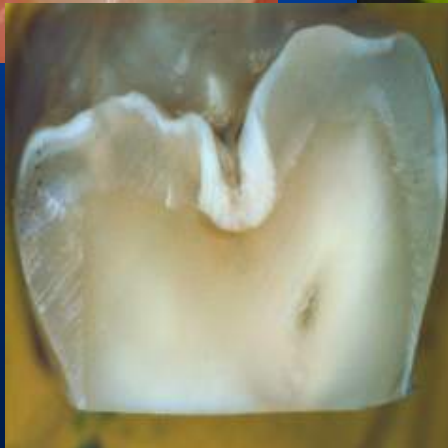
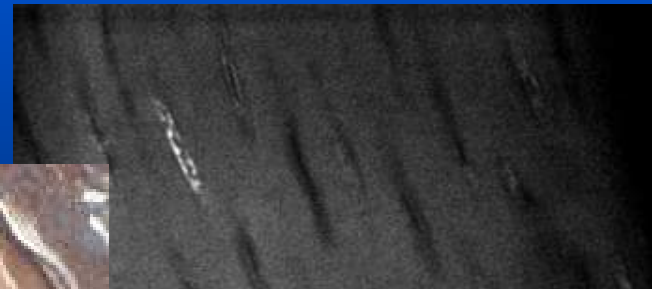
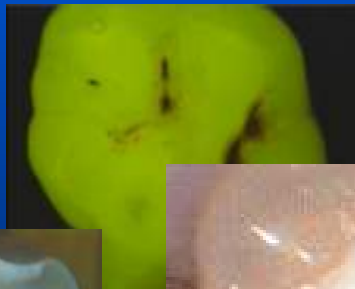

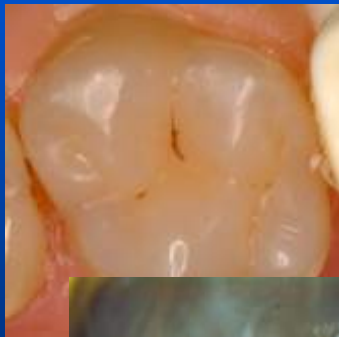
# *Sealing Non-Cavitated Caries Lesions: Implications For Practice*

*Margherita Fontana, DDS, PhD*

**Indiana University School of Dentistry**

**Department of Preventive and Community Dentistry**



**NATIONAL INSTITUTES OF HEALTH  
CONSENSUS DEVELOPMENT CONFERENCE  
Diagnosis and Management of Dental Caries  
Throughout Life (March 26-28, 2001)**

- “Improved caries detection and diagnostic methods would help determine the appropriate **cutpoint or threshold** separating the **clinical decisions** to do nothing or preventively seal, or to therapeutically seal or surgically treat and restore”

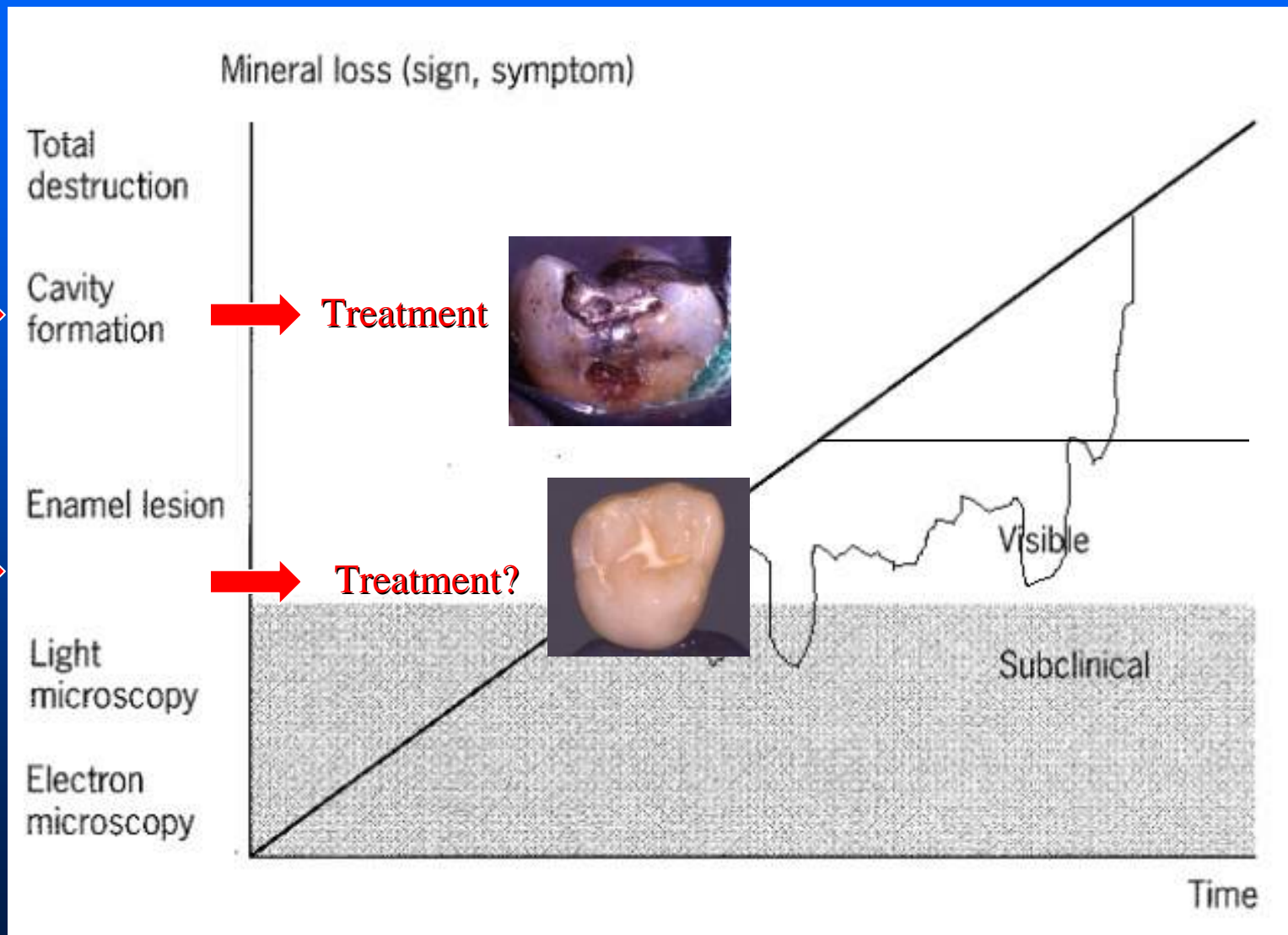
(Weintraub, 2001)

# Progress of Mineral Loss/Detection

Disease →

(White Spot)

Disease →



Slide 3

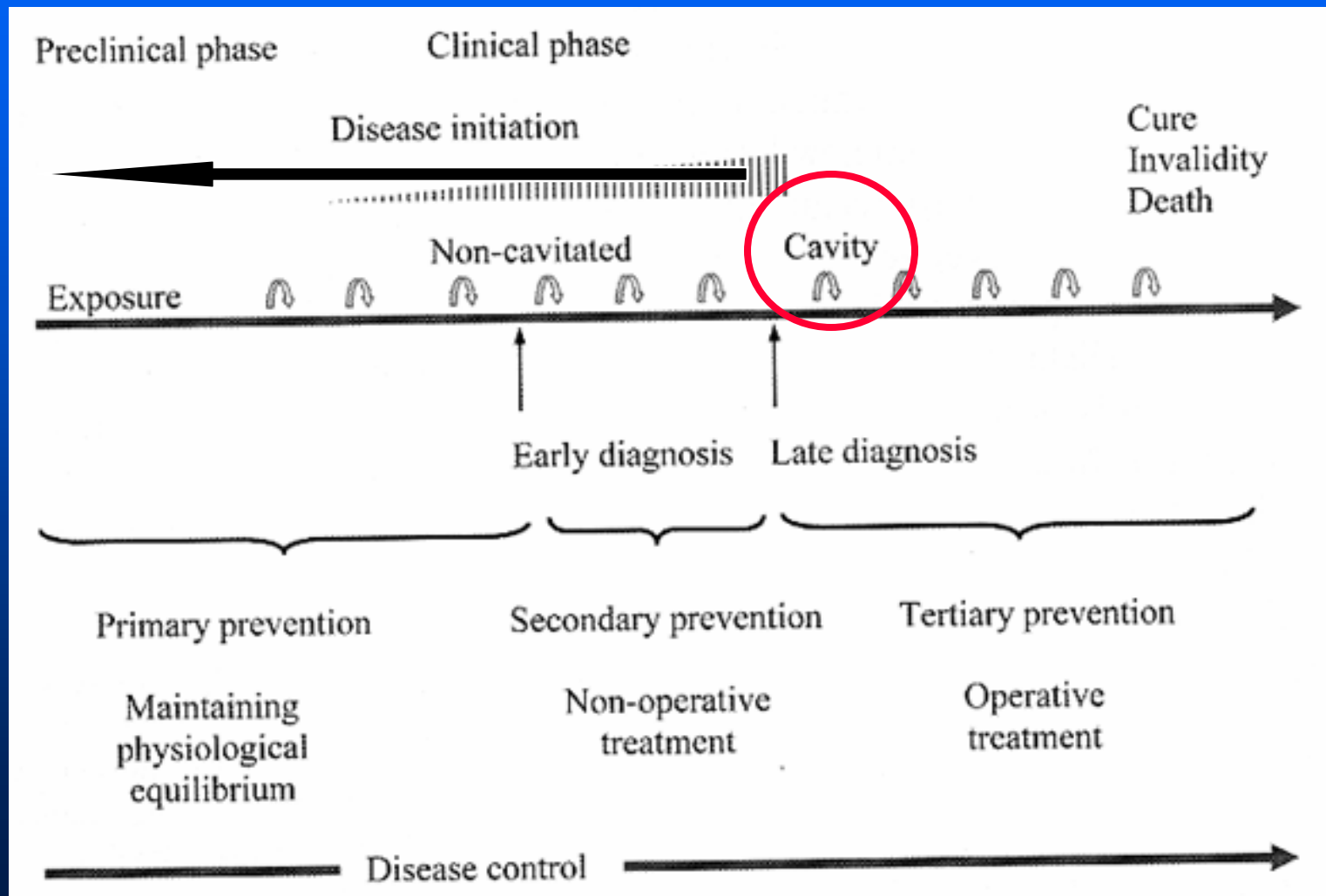
---

m8

White spots can also be in dentin....

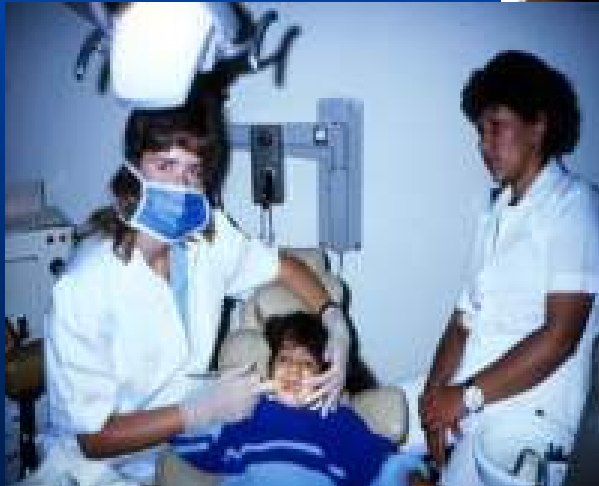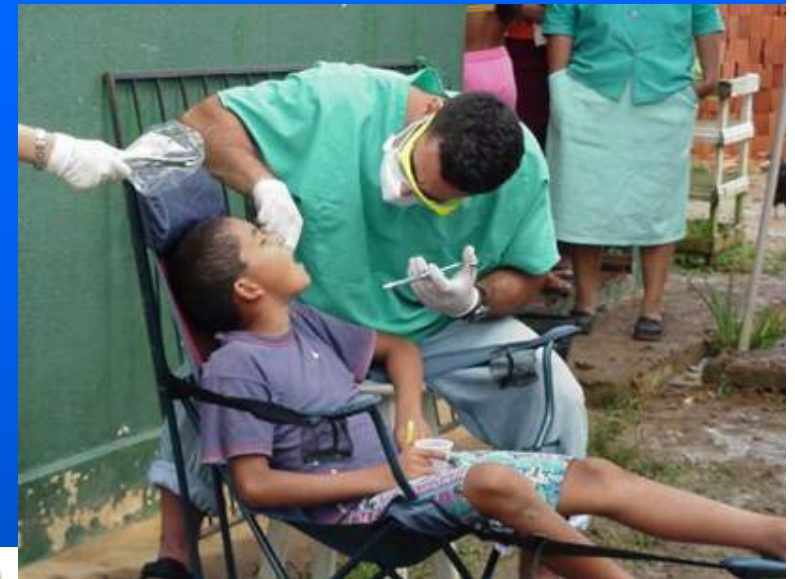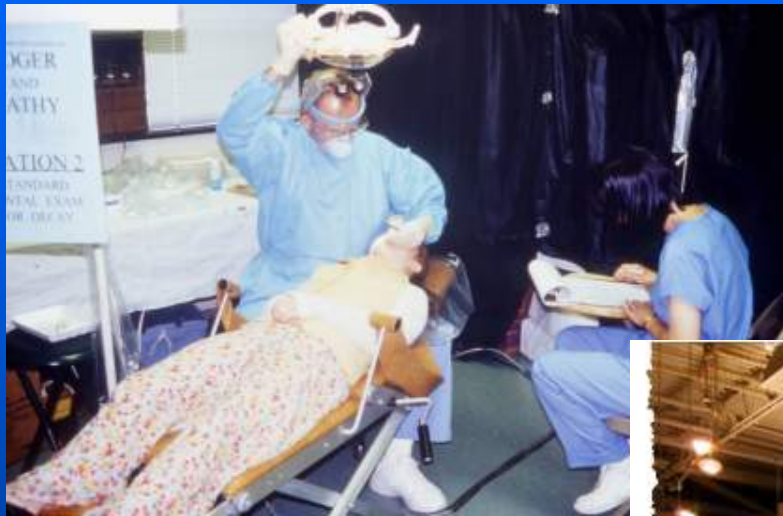mfontan, 2/25/2005

# What Level Of Assessment Do We Need For Sealant Placement In Any Setting?



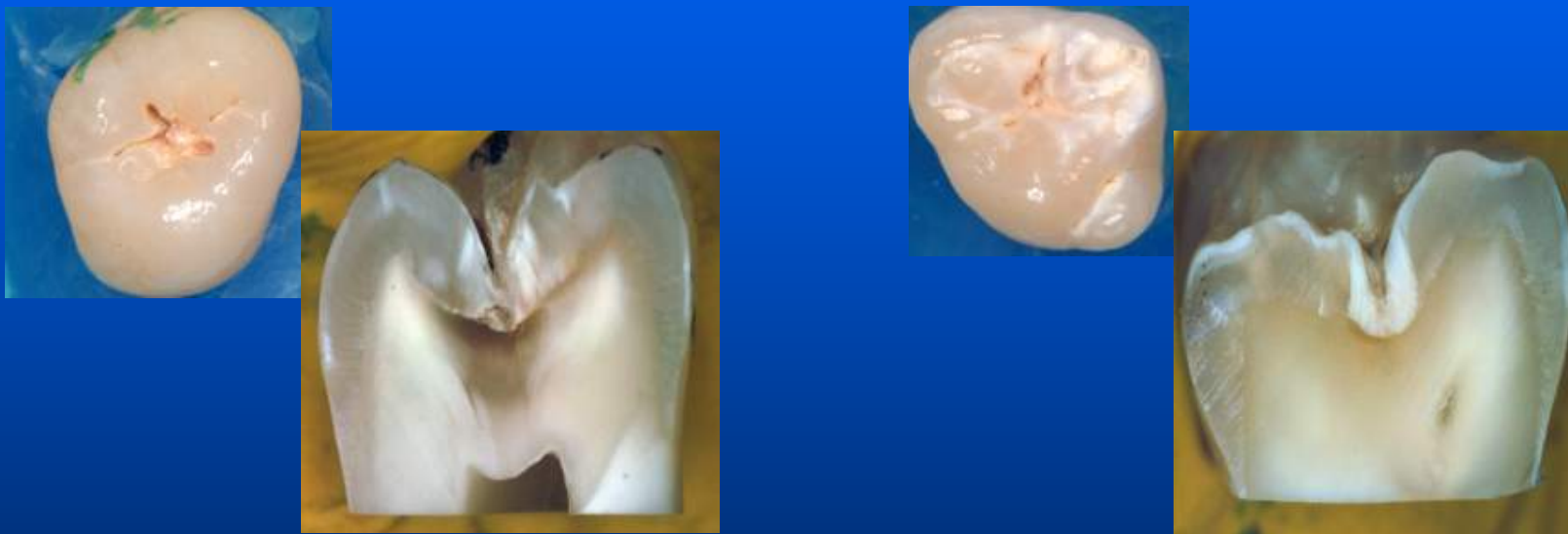

**Variety of options change by setting, but the scientific evidence supporting management strategies should be the same**



**Professional leadership has advocated that any fissure lesion judged to be limited to enamel is a candidate for sealant therapy (Siegel, 1995, 2002)**

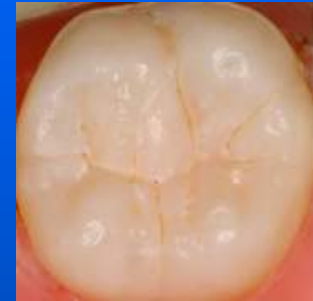**Can we judge when caries is in enamel?**



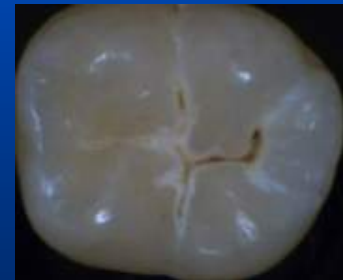**Is the presence of cavitation a more practical sign of the need for operative intervention?**

# Indications for Occlusal Sealants

➤ On sound, at risk surfaces



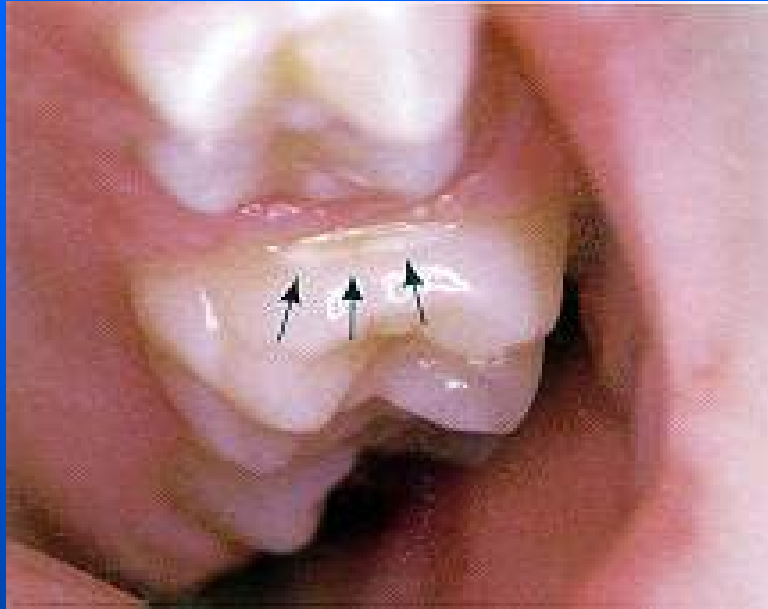➤ To arrest questionable or non-cavitated (incipient) caries lesions



**What is a non-cavitated caries lesion?**



# Stages of the Disease



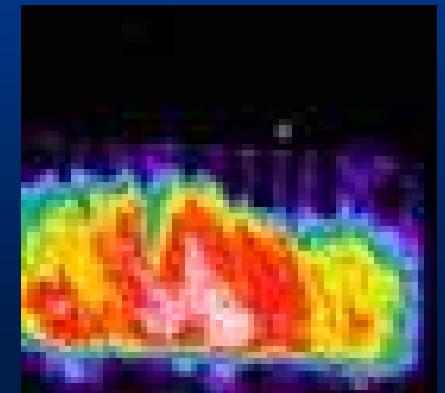
## White Spot /Non-Cavitated Lesion:

It is a subsurface lesion



Internal  
loss of  
minerals

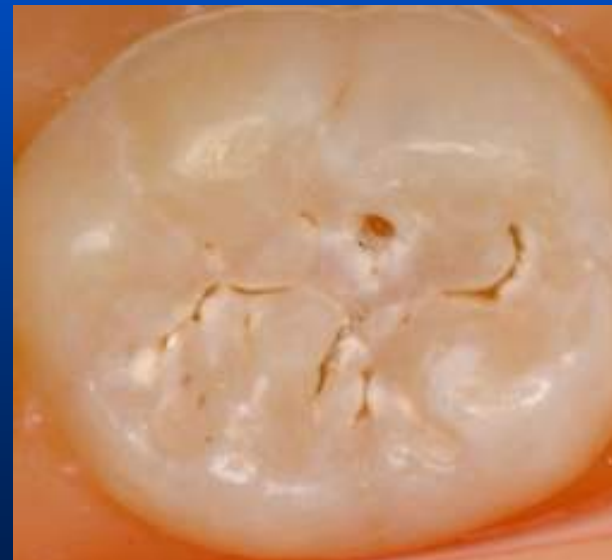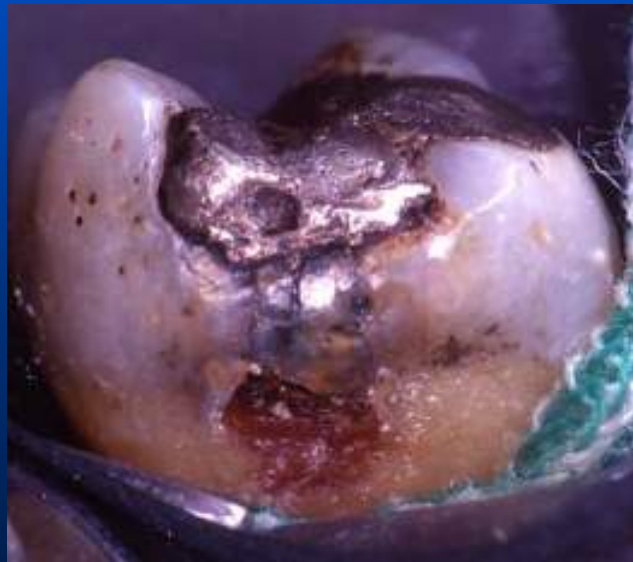External  
(outer)  
surface



# Stages of the Disease

## *Cavitated Lesion (Cavity):*

- ✓ A caries lesion that has lost the outer surface (leading to a discontinuity in the surface)



**Slide 9**

---

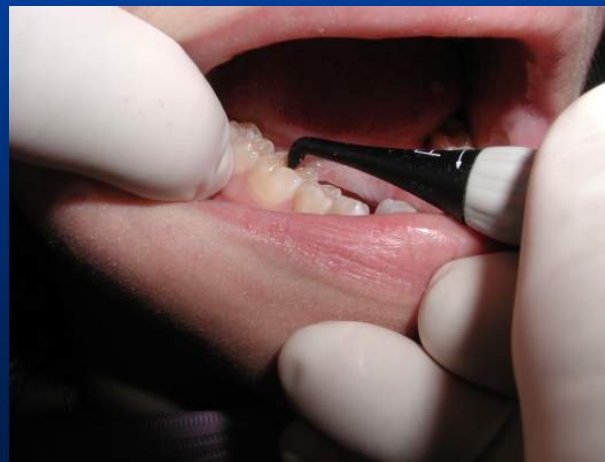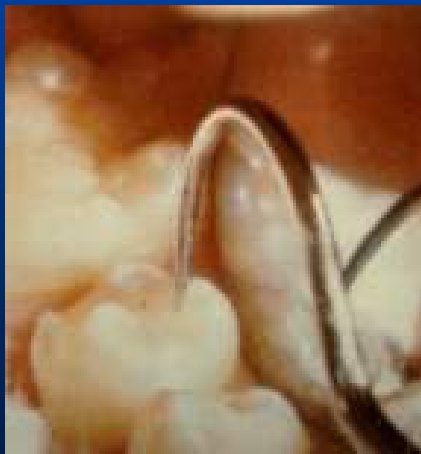**MF5**

What is referred to as a cavity in need of operative intervention, based on the previous slide by Kidd, may change with magnification

Margherita Fontana, 4/26/2006

# Scientific Evidence for Caries Detection

- 2001 NIH Consensus Development Conference - Systematic Review
- ICDAS II
- Selected studies

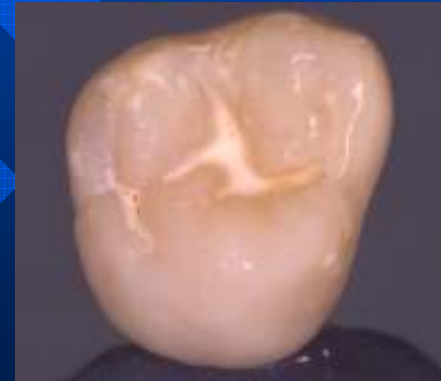

**NATIONAL INSTITUTES OF HEALTH  
CONSENSUS DEVELOPMENT CONFERENCE  
Diagnosis and Management of Dental Caries  
Throughout Life (March 26-28, 2001)**

“At this time the panel senses a paradigm shift in the management of dental caries toward improved **diagnosis** of **early non-cavitated lesions** and treatment for prevention and arrest of such lesions”

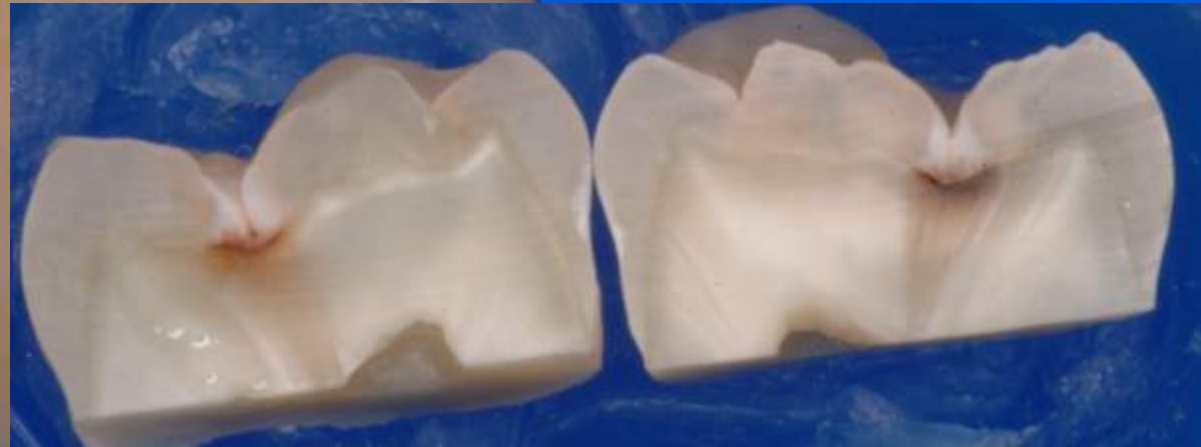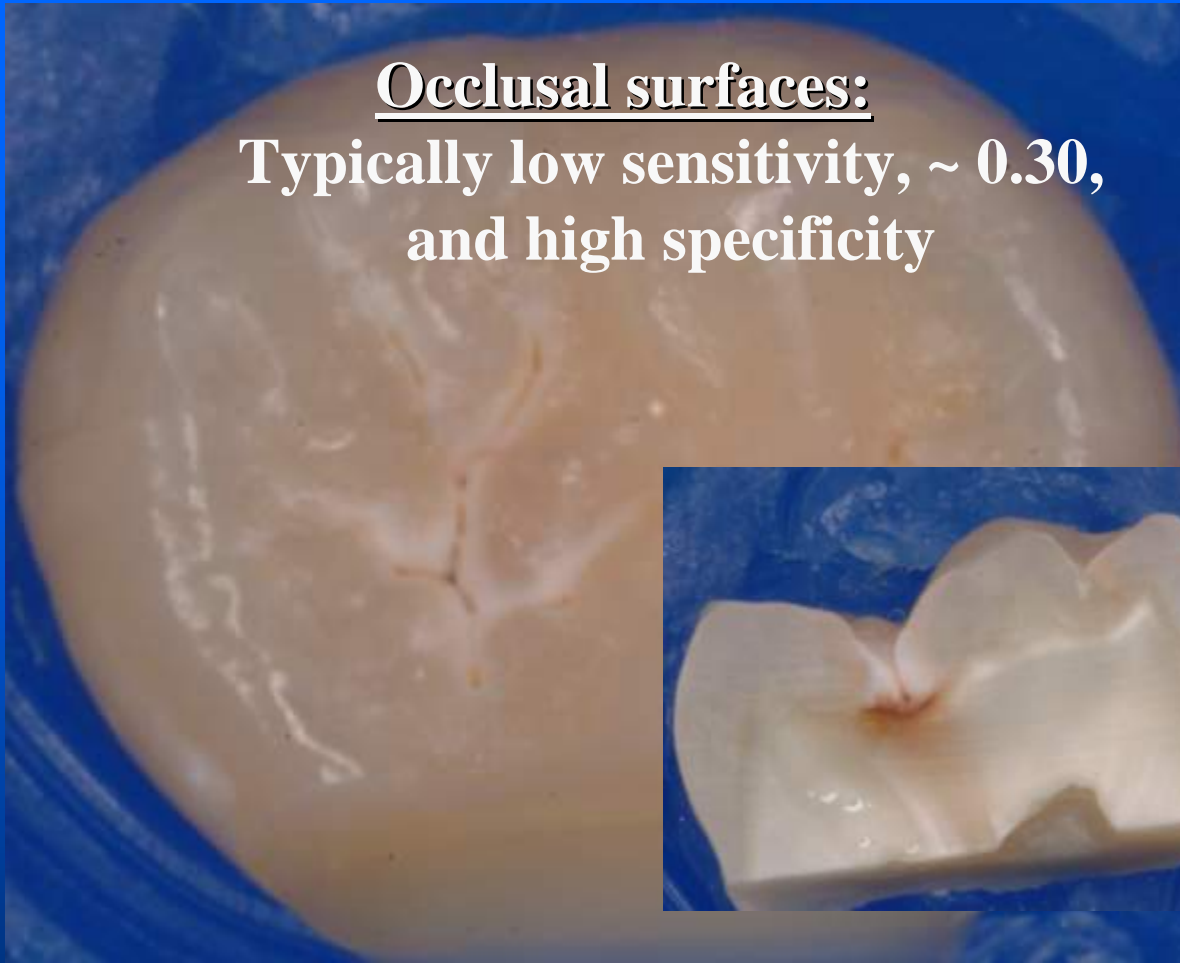[http://odp.od.nih.gov/consensus/cons/115/115\\_statement.htm](http://odp.od.nih.gov/consensus/cons/115/115_statement.htm)

**What level of assessment  
do we need for sealant  
placement in School-  
Based Programs?**



Occlusal surfaces:

Typically low sensitivity, ~ 0.30,  
and high specificity



“Clearly, since our diagnostic methods for assessing pit and fissure caries have been up to this time basically an educated guess, we must be placing sealants almost routinely over undetected incipient lesions” (Simonsen, 2002)



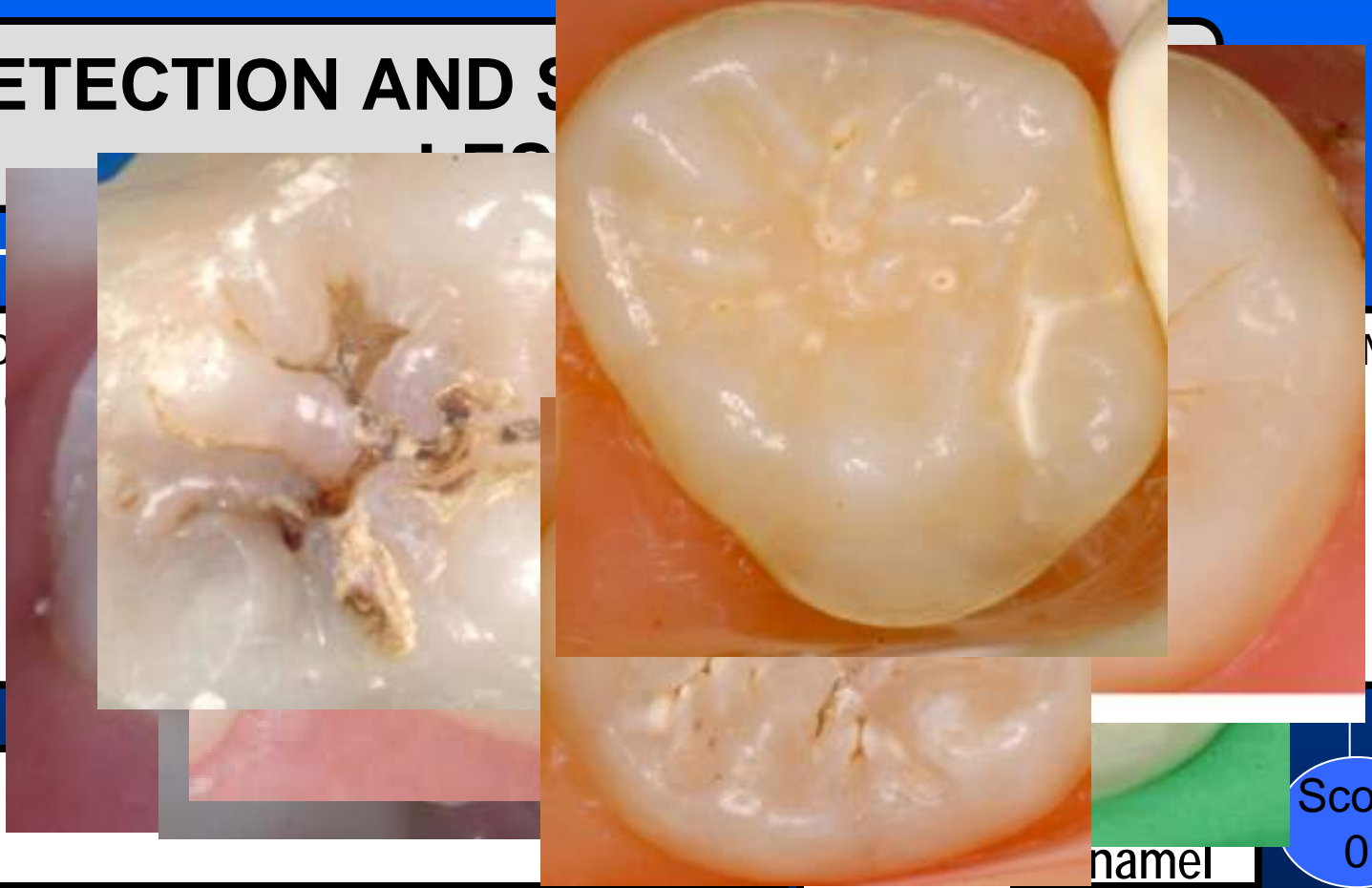# ICDAS-2

<http://www.icdas.htm>

*Suggested cut-off point:  
Between ICDAS 2 and 3*

DETECTION AND S

EXTENSIVE  
CAVITY



ND

Score  
0

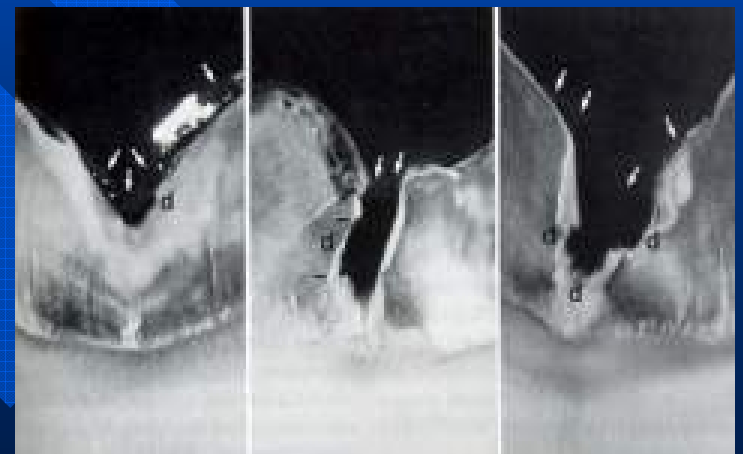
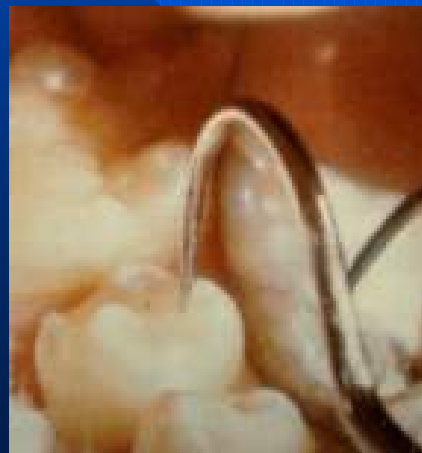Enamel

Enamel/  
Dentin

# Probing with Sharp Explorer...

Traditional probing with a sharp explorer has come into question as the ultimate determinant of caries activity. **The exclusive use of a “catch” by the sharp explorer to diagnose caries in pit and fissure sites should be discontinued** and clinicians are being called upon to use “sharp eyes and a blunt explorer.” Also **non-cavitated lesions can become cavitated** simply through pressure from the explorer during the typical examination.

**Treating caries as an infectious disease. JADA 125 (June): 2-S to 15-S (1995)**

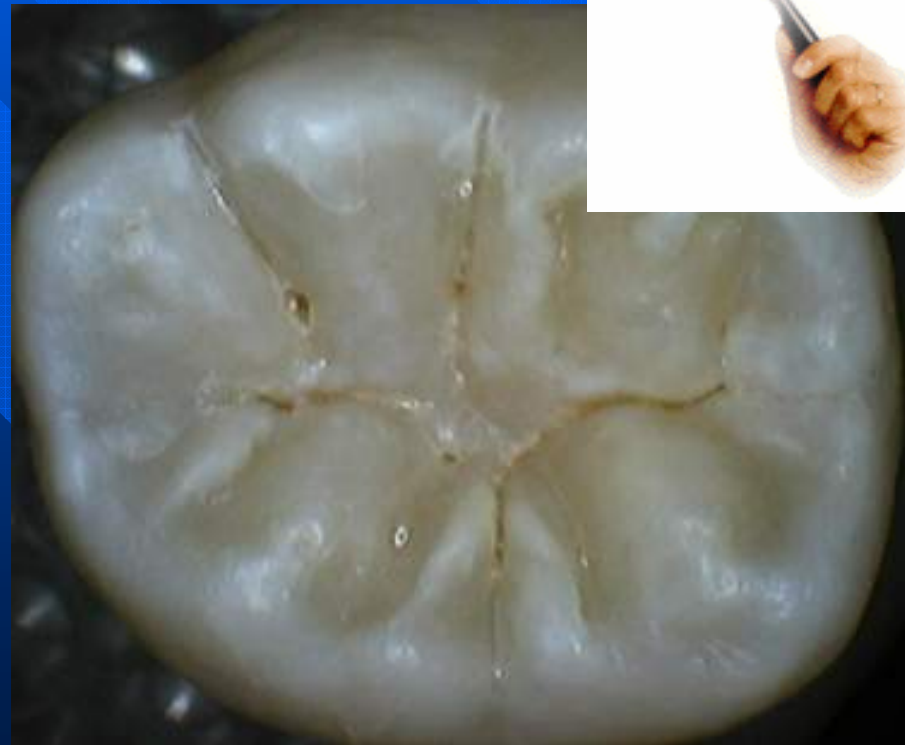
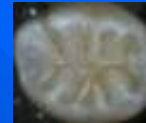
*Ekstrand et al., 1987*

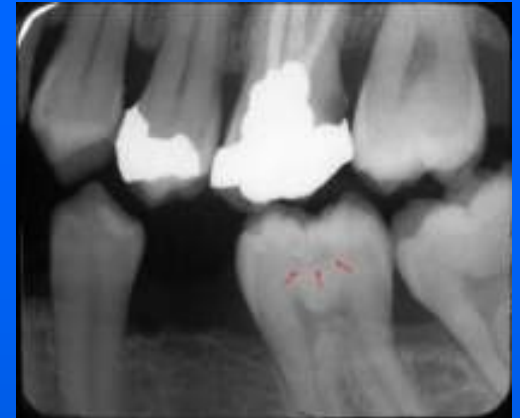# Role of Magnification in Determining Cavitation

- Magnification is not necessary to detect lesions using the ICDAS-2 criteria
- Its use may affect the interpretation of the histological findings in relation to the criteria developed to correlate with it.

For example, a category 2 tooth could be viewed as a category 3 under magnification, and this would result in more teeth being eliminated from consideration of sealants.

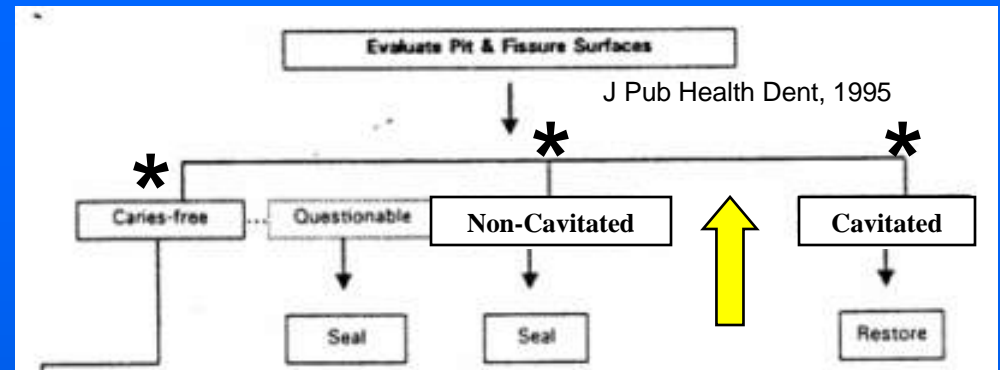


# Radiographic Examination



- ✓ Radiographs show that demineralization is present, but when looked at in one period of time they cannot determine ACTIVITY
- ✓ Incidence of interproximal lesions in 2-3 graders is low
- ✓ The ICDAS-2 criteria recognizes that some of the non-cavitated stages of the caries disease process may have already progressed into dentin

# Summary



## ■ How do we assess cavitated vs. non-cavitated lesions?

- Visual assessment is appropriate
- Teeth can be dried with cotton rolls, gauze, or compressed air
- Explorer may be used to clean the fissures and “gently” confirm cavitations (i.e., breaks in the continuity of the surface); do not use sharp explorer under force
- Magnification (2x-4x) can be used, but is not required
- Radiographs are unnecessary, especially in programs targeting children in grades 2 – 3
- Insufficient evidence to recommend other technologies to determine presence or absence of cavitation

## Slide 17

---

**bf6**

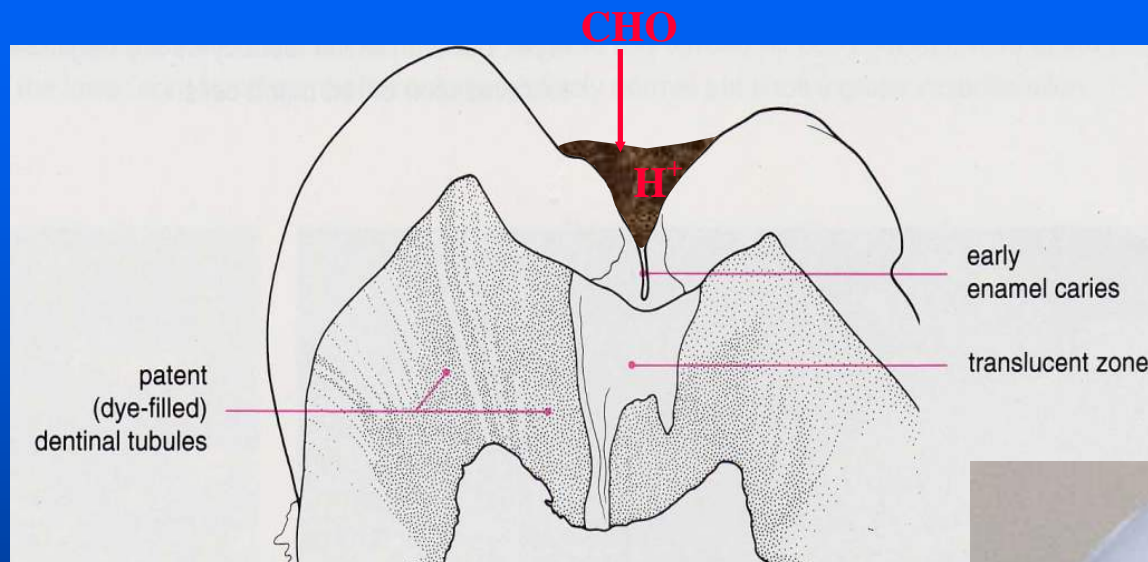
We suggest that you enlarge graphic "evaluate pit and fissure surfaces" and then bring each bullet in and then fade that bullet before bringing in the next bullet. In this way you will only need space for the questions and one answer at a time.

Barbara Finigan Gooch, 4/17/2007

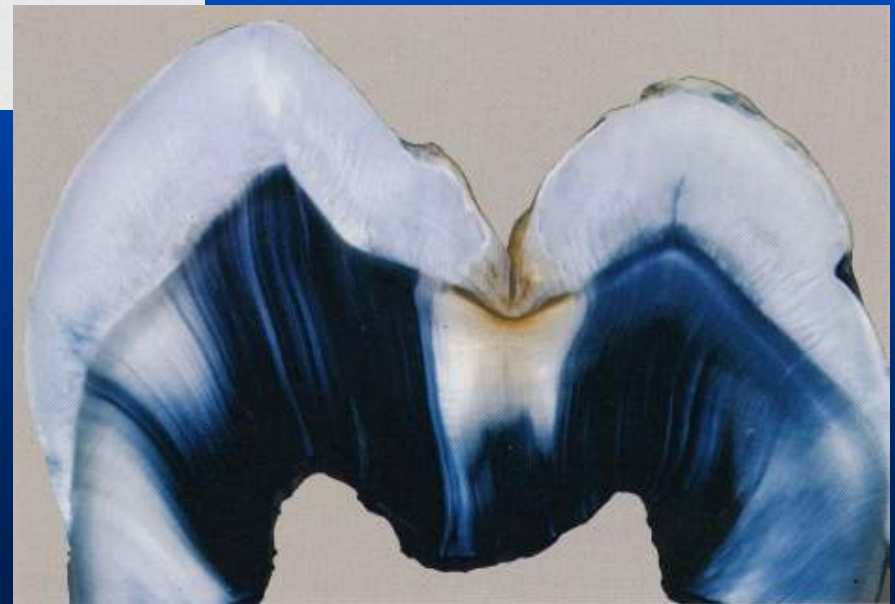

**Thank You**

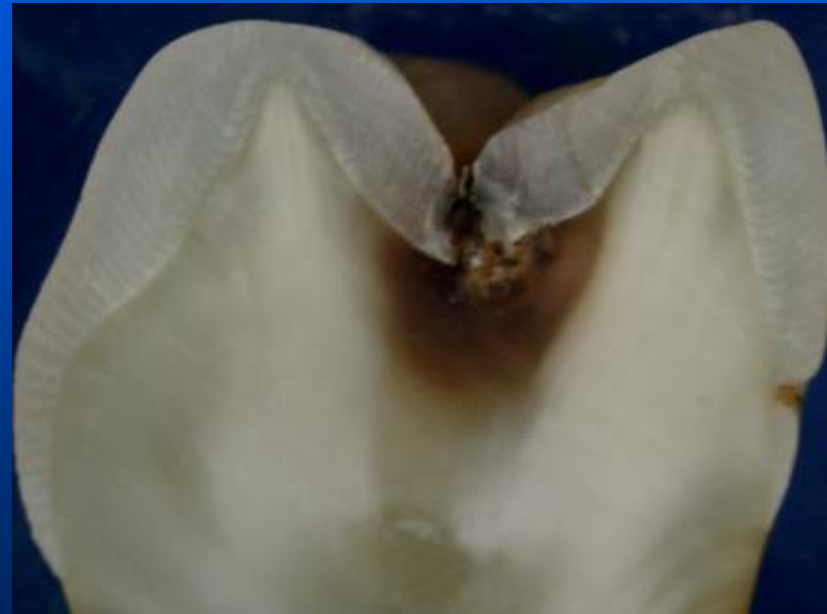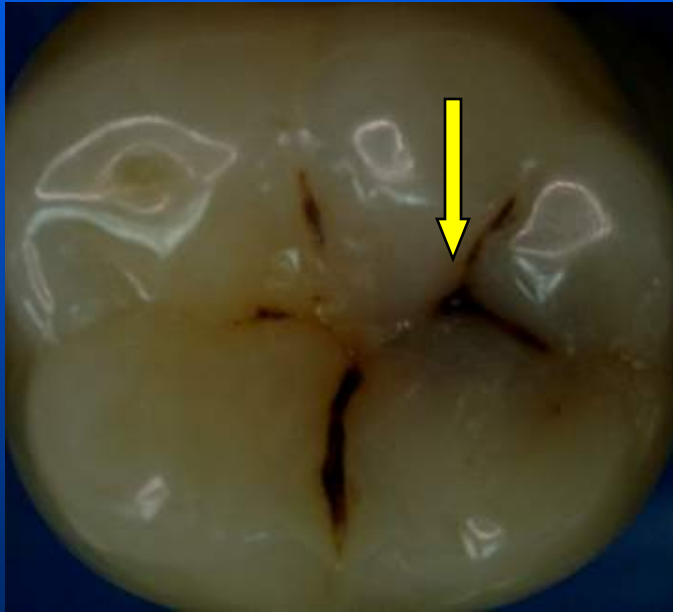
# What is the Caries Disease Process?



**The metabolic activity of the biofilm on the surface is the driving force...**

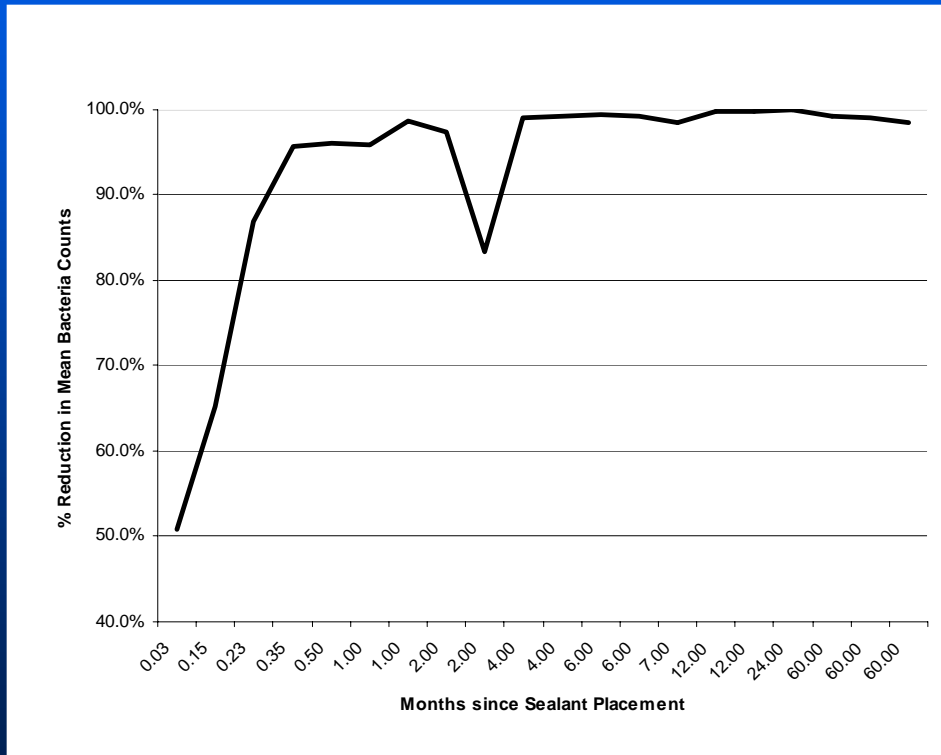


**...and/or is it the infected dentin  
once the lesion cavitates?**



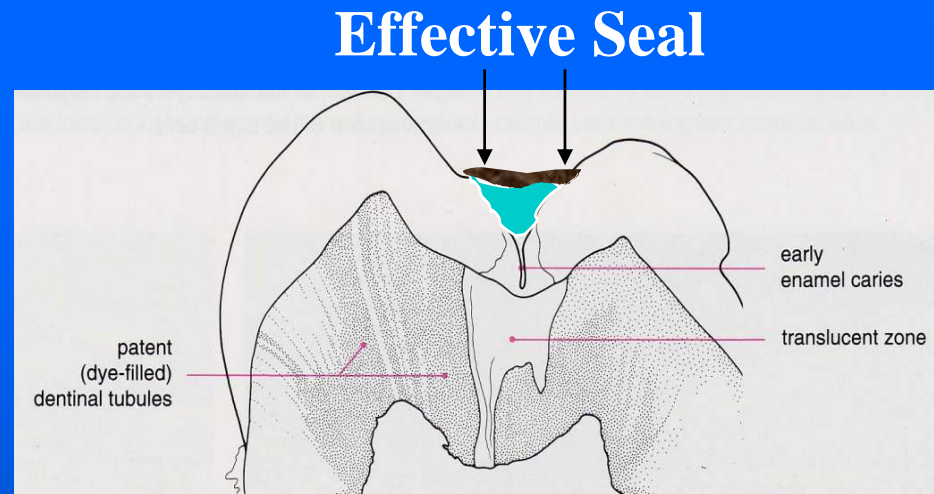
# Reduction in Bacteria Counts by Time since Sealant Placement

(Griffin et al., 2007)



- The percentage reduction in mean bacteria counts (4 studies) ranged from 50.8% to 99.9% and appeared to increase as time since sealant placement increased.

# Dental Sealants



## Sealing infected dentin changes the oral environment (Kidd, 2004):

- encourages arrest of demineralization,
- tubular sclerosis and tertiary dentin are encouraged,
- dentin permeability is reduced,
- residual microorganisms are now in a different environment (do they change? how do they survive?)...they may become irrelevant!

# **Implications for Practice**

**Sealing non-cavitated lesions is an appropriate management alternative for these lesions**



*Thank you...*

